



## Esophageal cancer radiotherapy

## Feasibility of tomotherapy to reduce normal lung and cardiac toxicity for distal esophageal cancer compared to three-dimensional radiotherapy

Nam P. Nguyen<sup>a,\*</sup>, Shane P. Krafft<sup>a</sup>, Vincent Vinh-Hung<sup>b</sup>, Paul Vos<sup>c,d</sup>, Fabio Almeida<sup>a</sup>, Siyoung Jang<sup>a</sup>, Misty Ceizyk<sup>a</sup>, Anand Desai<sup>a</sup>, Rick Davis<sup>a</sup>, Russ Hamilton<sup>a</sup>, Homayoun Modarresifar<sup>d</sup>, Dave Abraham<sup>a</sup>, Lexie Smith-Raymond<sup>a</sup>

<sup>a</sup> Department of Radiation Oncology, University of Arizona, Tucson, AZ, USA; <sup>b</sup> Department of Radiation Oncology, University Hospitals of Geneva, Switzerland; <sup>c</sup> Department of Biostatistics, East Carolina University, Greenville, NC, USA; <sup>d</sup> Department of Radiology, University of Arizona, Tucson, AZ, USA

## ARTICLE INFO

## Article history:

Received 21 November 2010  
Received in revised form 16 June 2011  
Accepted 24 July 2011  
Available online 9 September 2011

## Keywords:

Distal esophageal cancer  
Tomotherapy  
Normal tissue sparing

## ABSTRACT

**Purpose:** To compare the effectiveness of tomotherapy and three-dimensional (3D) conformal radiotherapy to spare normal critical structures (spinal cord, lungs, and ventricles) from excessive radiation in patients with distal esophageal cancers.

**Materials and methods:** A retrospective dosimetric study of nine patients who had advanced gastroesophageal (GE) junction cancer (7) or thoracic esophageal cancer (2) extending into the distal esophagus. Two plans were created for each of the patients. A three-dimensional plan was constructed with either three (anteroposterior, right posterior oblique, and left posterior oblique) or four (right anterior oblique, left anterior oblique, right posterior oblique, and left posterior oblique) fields. The second plan was for tomotherapy. Doses were 45 Gy to the PTV with an integrated boost of 5 Gy for tomotherapy. **Results:** Mean lung dose was respectively 7.4 and 11.8 Gy ( $p = 0.004$ ) for tomotherapy and 3D plans. Corresponding values were 12.4 and 18.3 Gy ( $p = 0.006$ ) for cardiac ventricles. Maximum spinal cord dose was respectively 31.3 and 37.4 Gy ( $p < 0.007$ ) for tomotherapy and 3D plans. Homogeneity index was two for both groups.

**Conclusions:** Compared to 3D conformal radiotherapy, tomotherapy decreased significantly the amount of normal tissue irradiated and may reduce treatment toxicity for possible dose escalation in future prospective studies.

© 2011 Elsevier Ireland Ltd. All rights reserved. Radiotherapy and Oncology 101 (2011) 438–442

In 2009, there were 16,470 new cases of esophageal cancer in the US. It was estimated that 14,530 will die from the disease because most cases were advanced at presentation [1]. For inoperable patients, standard of care has been concurrent chemoradiation [2]. Radiation dose was usually limited to 50 Gy in the US because of the increased toxicity associated with a higher dose without survival improvement [3]. However, two recent randomized studies in Europe reported improved survival comparable to surgery in locally advanced thoracic esophageal cancer undergoing definitive chemoradiation with tumor dose up to 70 Gy [4,5]. Long-term survival and improved local control was reported with accelerated hyperfractionation to 68 Gy and chemotherapy in another randomized study for locally advanced esophageal cancer [6]. Toxicity was significant, with 6% of the patients dying from the treatment [6]. Thus, a radiotherapy technique that reduces treatment toxicity while providing a curative dose of radiation to the tumor may improve survival and local control.

Lung and cardiac toxicities are the limiting factors for radiation dose escalation if the tumors extend to the lower third of the esophagus or for gastroesophageal (GE) junction tumors. Intensity-modulated radiotherapy (IMRT) has been introduced to improve target coverage while potentially decreasing the radiation dose to the normal tissues [7–10]. However, cardiac toxicity remains significant even with the IMRT technique because of high radiation dose to the heart [11,12]. In addition to IMRT, recent advances in radiotherapy include image-guided radiotherapy (IGRT) techniques permitting pre-therapy visualization of target volumes and normal tissues. Compared to IMRT, image-guided radiotherapy may provide better sparing of the cardiac structures because of improved visualization of the tumor similar to other sites such as head and neck cancer [13].

Helical tomotherapy is an image-guided radiotherapy technique incorporating daily megavoltage computed tomography (MVCT) imaging and dynamic rotational IMRT [14]. The combination of precise target visualization leading to reduced planning target volumes via IGRT, and more precise dose delivery via IMRT, should lead to further reduction of irradiated heart, lungs, and spinal cord [15]. Thus, we conduct this retrospective dosimetric

\* Corresponding author. Address: Department of Radiation Oncology, University of Arizona, 1501 N. Campbell Ave., Tucson, AZ 85724-5081, USA.

E-mail address: NamPhong.Nguyen@yahoo.com (N.P. Nguyen).

study to assess the effect of tomotherapy on normal tissues compared to the conventional three-dimensional radiotherapy technique (3DCRT).

## Materials and methods

### Patient and tumor characteristics

The medical records of nine patients undergoing radiotherapy for esophageal cancer at the Department of Radiation Oncology, University of Arizona were retrospectively identified following institutional review board (IRB) approval. Patients were selected if they had tumor at the GE junction (7) or locally advanced thoracic esophageal cancer extending into the lower third of the esophagus (2). Except for one patient, all had positron emission tomography for staging. Table 1 summarizes patient characteristics.

### Treatment characteristics

All patients were treated on the TomoTherapy Hi-Art II helical tomotherapy unit (HT) (TomoTherapy Inc., Madison, WI). The HT treatments deliver six MV photons without a flattening filter. Intensity modulation is achieved using a binary multileaf collimator (MLC) having 64 leaves with widths that project to a 6.25 mm width at the bore center (isocenter), which is 85 cm away from the X-ray photon source. The HT has been commissioned for 1.0, 2.5, and 5 cm jaw models. The HT plans were helically delivered from 51 beam angles per rotation. A tomotherapy treatment planning station, version 2.1.2 was used for the HT plans. The delineations of the target and organs at risk (OAR) for complications were performed on a Pinnacle planning station (Phillips) and the CT dataset with contoured structures was transferred to the tomotherapy planning station. Parameters for beamlet calculation were a field width of 5 cm, pitch of 0.287, and normal resolution mode. The maximum modulation factor for the plan optimization was two. A dose calculation grid ( $3.76 \times 3.76 \times 3 \text{ mm}^3$ ) was used for all patients.

**Table 1**  
Patient characteristics.

Patient number	9
Age	
Median	67
Range	50–86
Sex	
Male	7
Female	2
Histology	
Adenocarcinoma	7
Squamous	2
T stage	
T1	1
T2	1
T3	7
N stage	
0	2
1	4
2	3
Stage	
IIB	3
IIIA	5
IIIB	1
Treatment	
Declines treatment	1
Radiotherapy alone	1
Preoperative chemoradiation	1
Postoperative chemoradiation	2
Definitive chemoradiation	4
Mean PTV volume (cc)	256.5 (212–342.6)

### Target volume delineation

Prior to treatment, each patient was simulated in the supine position with a body vacuum bag for treatment immobilization. A computed tomography (CT) scan with and without oral and intravenous (IV) contrast for treatment planning was performed in the treatment position. The chest and upper abdomen were scanned with a slice thickness of 3 mm. CT scan with oral and IV contrast was employed to outline the tumor and grossly enlarged regional lymph node for target volume delineation. Radiotherapy planning was performed on the CT scan without contrast to avoid possible interference of contrast density on radiotherapy isodose distributions. Diagnostic positron emission tomography (PET)-CT scan planning for tumor imaging was also incorporated with CT planning for eight patients.

Normal organs at risk for complication were outlined for treatment planning (spinal cord, cardiac ventricles, lungs, kidney, liver, and bowels). The cardiac ventricles (right and left) were contoured on the contrast CT scan. The gross tumor volume (GTV) was outlined by integrating information obtained from the CT scan with IV and oral contrast study and PET scan when available. The GTV was expanded by 1 cm radially and 5 cm superiorly and inferiorly to for thoracic esophageal cancer CTV. For GE junction cancer, the upper, inferior, and radial CTV was 5, 3, and 1 cm, respectively. The CTV was expanded with a 0.3-cm radial expansion for esophageal PTV as we assume that daily MV CT scan would allow a tighter PTV radial margin because of improved target visualization. In addition, it is our policy that the MVCT and the radiation dose distribution are checked by the radiation oncologist prior each treatment to avoid marginal miss. The celiac lymph nodes with a 1 cm margin were also included in the CTV for all patients with an expansion of 0.5 cm for PTV coverage. Any mediastinal lymph nodes enlargement observed on CT scan and/or PET scan was also included in the CTV with 5 mm PTV expansion.

The PTV and the GTV were treated to 45 Gy at 1.8 Gy/fraction and 50 Gy at 2 Gy/fraction, respectively. Dose constraints for normal organs at risk (OAR) for complications were: spinal cord (45 Gy), total lung ( $V_5 < 50\%$ ,  $V_{10} < 40\%$ ,  $V_{15} < 30\%$ , and  $V_{20} < 25\%$ ), cardiac ventricles (10 Gy  $< 50\%$ ), liver ( $V_{30} < 30\%$ ), kidneys ( $V_{15} < 30\%$ ), and bowels (45 Gy  $< 50\%$ ).

The following optimization constraints were applied during the planning process for tomotherapy: for tumors, the importance value was set to 50, and maximum and minimal dose penalties were set to 100. For organ at risk, the importance value was set to 15, and maximal and minimal dose penalties were set to 1 and 20, respectively. Among the OAR, the cardiac ventricles received the most priority for dose restriction because of the close proximity of the tumor to the heart. Once the optimization was completed, the radiation oncologist reviewed the isodose distributions for final approval of the treatment plans.

A CT scan of chest and abdomen was repeated at 40 Gy to assess tumor response to treatment in patients undergoing radiotherapy alone or definitive chemoradiation for possible boost to the GTV after 50 Gy.

### Dosimetric comparison between helical tomotherapy and 3D plans

For the purpose of the study, the PTV was re-planned with the 3D conformal technique to assess whether there was a dosimetric advantage in treating the patients with the IGRT technique. For direct comparison, a total dose of 45 Gy to the PTV was planned with the 3D conformal technique with no sequential boost. The beam arrangement was either three fields (anteroposterior (AP), right posterior oblique (RPO), and left posterior oblique (LPO)), or four fields (right anterior oblique (RAO), left anterior oblique (LAO), RPO and LPO) for the 3D conformal technique to minimize the dose

to the cardiac ventricles. The 3D plan was performed on Pinnacle with a combination of 6 and 15 MV photons beams with wedges attempting to maintain dose homogeneity. A minimum of 95% coverage was required for both tomotherapy and 3D plans. The homogeneity index was calculated for both tomotherapy and 3D plans based on the equation:  $HI = 100 \times (D_2 - D_{98})/D_p$  where  $D_2$  and  $D_{98}$  are the doses to 2% and 98% of the PTV and  $D_p$  is the prescription dose [16]. Statistical analysis was performed with the paired *t*-test. *p*-Values below 0.05 are considered statistically significant.

## Results

Even though the dose to the GTV was higher (50 Gy) for tomotherapy compared to the 3D conformal technique, beam optimization provided significant dose reduction to the normal structures with IGRT. Maximum spinal cord dose was respectively 31.3 Gy (range: 22.7–37.6 Gy) and 37.4 Gy (range: 28.8–44 Gy) for tomotherapy and 3D conformal radiotherapy (95% confidence interval: 2.1 to 10.1) ( $p = 0.007$ ). Mean lung dose was respectively 7.4 Gy (range: 4.6–11.4 Gy) and 11.8 Gy (range: 3.4–18.9 Gy) for tomotherapy and 3D conformal radiotherapy (1.6–6.2) ( $p = 0.004$ ). Corresponding values were respectively 12.4 Gy (range: 7.8–20.2 Gy) and 18.3 Gy (range: 8.2–28 Gy) for the cardiac ventricles (2.3–9.5) ( $p = 0.005$ ). A significant reduction of the volume of normal lungs irradiated to 5 Gy ( $V_5$ ), 10 Gy ( $V_{10}$ ), 15 Gy ( $V_{15}$ ), and 20 Gy ( $V_{20}$ ) was observed with tomotherapy.  $V_5$ ,  $V_{10}$ ,  $V_{15}$ , and  $V_{20}$  was respectively 41.2% and 56% (4.1–25.7) ( $p = 0.013$ ), 23% (10.3–29.8) ( $p = 0.001$ ), 16.4% and 34% (9.1–26.1) ( $p < 0.001$ ), and 11.9% and 24.1% (4.7–19.8) ( $p = 0.006$ ) for tomotherapy and 3D. A significant reduction of the volume of cardiac ventricles irradiated above 15 Gy was also observed with tomotherapy. The cardiac ventricles  $V_{15}$ ,  $V_{20}$ ,  $V_{25}$ ,  $V_{30}$ , and  $V_{40}$  were respectively 27.1% and 52.6% (13.2–37.8) ( $p = 0.001$ ), 15.4% and 47.5% (20.1–44.1) ( $p < 0.001$ ), 9.3% and 37.8% (15.3–41.8) ( $p = 0.001$ ), 5.7% and 24.8% (8.0–30.1) ( $p < 0.004$ ), and 5% and 1.4% (1.0–6.2) ( $p = 0.013$ ) for tomotherapy and 3D plan. However, compared to 3D, tomotherapy was associated with a non-significant increase of cardiac  $V_5$  and a non significant reduction of cardiac  $V_{10}$ . The cardiac ventricles  $V_5$  and  $V_{10}$  were respectively 97.2% and 73.7% (–31.5 to 4.4) ( $p = 0.1$ ) and 48.8% and 58.9% (–8.4 to 28.6) ( $p = 0.2$ ) for tomotherapy and 3D plans. The mean homogeneity index was two for both groups. Figs. 1 and 2 summarize lung and cardiac ventricles doses obtained with both radiotherapy techniques.

## Discussion

Compared to the 3D conformal technique, tomotherapy provided significant dose reduction to the spinal cord, lung and cardiac ventricles in patients with distal or GE junction cancers. The effect of radiotherapy on the heart has been reported in many studies following conventional radiotherapy for esophageal cancers [11,12,17–21]. Sasamoto et al. [17] reported 11 out of 102 (10.7%) with severe cardiac silhouette enlargement following chemoradiation for esophageal cancer at a median follow-up of 15 months. Two of these 11 patients died from heart failure and were disease-free. Kumekawa et al. [18] observed nine patients with grade 3–4 cardiac ischemia (3), pericardial effusion (3), heart failure (3), and pleural effusion (3) in 110 patients who had chemoradiation for esophageal cancer. Four of these nine patients died from complications. Late cardiac complications were also corroborated by other studies with definitive chemoradiation or preoperative neoadjuvant chemoradiation for esophageal cancers [20,21]. Older patients (>70) were particularly at risk for cardiac complications most likely because of preexisting co-morbidities [21]. The high rate of cardiac complications following radiotherapy may be due

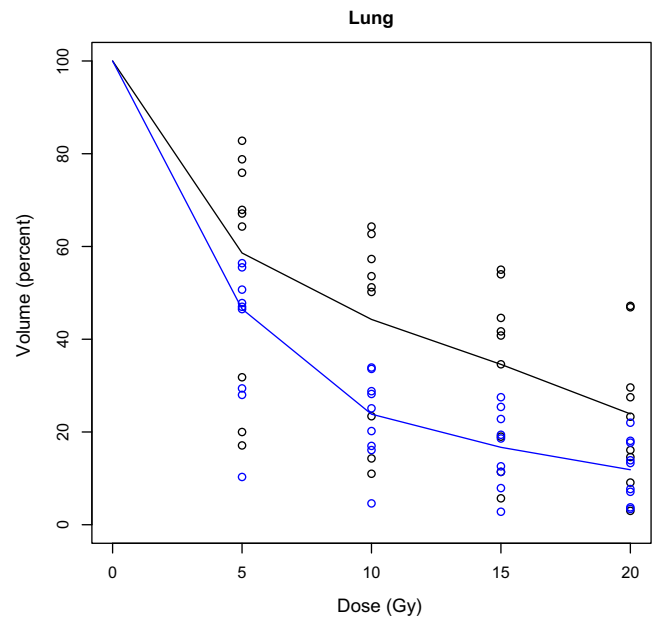


Fig. 1. Illustration of the lung volume receiving 5, 10, 15, and 20 Gy with three-dimensional conformal therapy (black line) and tomotherapy (blue line).

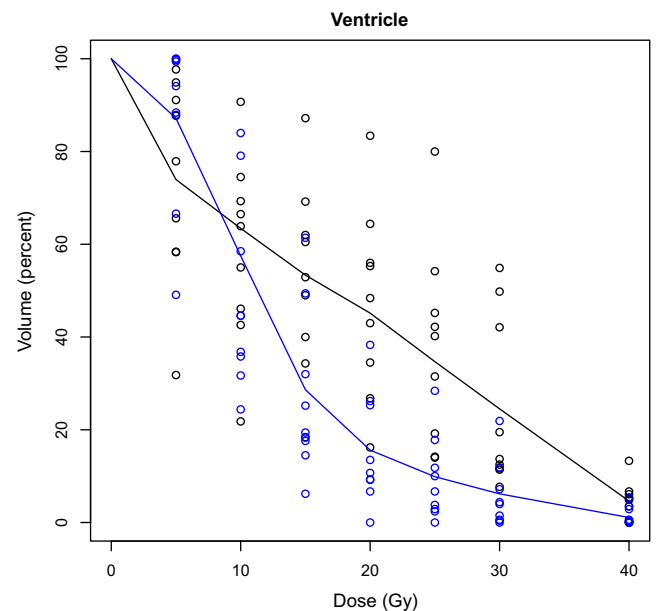


Fig. 2. Illustration of the cardiac ventricle volume receiving 5, 10, 15, 20, 25, and 30 Gy with the three-dimensional conformal (black line) technique and tomotherapy (blue line).

to multiple factors. Most patients with esophageal cancer had a history of smoking and drinking which predisposed them to coronary artery disease [22,23]. Standard chemotherapy agents for esophageal cancers, cisplatin (CP) and 5-fluorouracil (5-FU), were also associated with cardiac toxicity. Eskilsson et al. [22] reported cardiac events in 14 out of 76 (18%) patients undergoing induction chemotherapy with 5-FU and CP for their esophageal cancers. Chest pain, ST-T wave changes, atrial and ventricular fibrillation and sudden death were observed during chemotherapy. Both chemotherapy agents were used as radiosensitizers and may increase cardiac toxicity if the heart received a significant amount of radiation. Using gated myocardial perfusion imaging (MPI) to assess myocardial perfusion defect, Gayed et al. [11] reported a 54% rate of cardiac ischemia 3 months following chemoradiation for

esophageal cancers. Most perfusion defects were in the areas of the heart receiving more than 45 Gy. Patients with a history of congestive heart failure or cardiac arrhythmia were at increased risk of cardiac complications [12]. Other studies in childhood cancer survivors also corroborated the toxic effect of radiation and various chemotherapy agents (anthracycline, vinca alkaloid, antimetabolites, and alkylating agents) on the myocardium [24]. Thus, lowering radiation dose to the heart may be potentially life-saving. While IMRT may be beneficial in lowering cardiac toxicity, a significant percentage of the myocardium still received high radiation dose because of the proximity of the ventricles to the tumor. For example, Zhang et al. [9] reported that V40 and V50 (volume of the heart receiving 40 and 50 Gy) were 35% and 15%, respectively, in esophageal cancer patients treated with the IMRT technique. Technical advances with the IGRT technique provide the clinician with a unique opportunity to improve target coverage and increase radiation dose to the primary tumor and metastatic lymph nodes while minimizing radiation dose to the normal tissues. Helical tomotherapy has been proven to deliver a sharper dose gradient compared to conventional IMRT [25] and thus may be best suited to GE junction or distal esophageal cancers because of the close proximity of the tumor to the heart. We choose to contour the ventricles instead of the whole heart because the heart function is mainly dependent on the ventricles for its output. The cardiac ventricles receiving a high dose (above 15 Gy) were significantly lower with tomotherapy compared to 3D conformal technique. Because damage to the myocardium is related to heart volume receiving high radiation dose (45 Gy or more), tomotherapy may potentially reduce the morbidity of esophageal cancer radiotherapy. Increasing radiation dose to the tumor may also enhance the risk of severe pneumonitis related to radiation of a large volume of normal lungs [18–20,26–29]. As an illustration, patients who underwent preoperative chemoradiation for locally advanced esophageal cancer were usually selected based on adequate cardiac and pulmonary function prior to surgery. Preoperative radiotherapy dose ranged from 45 to 50 Gy in most studies. Among 61 patients who had conformal 3D radiotherapy for their esophageal cancer, 11 (18%) patients developed pneumonia or acute respiratory distress syndrome (ARDS) following surgery and two died (3%). Dose volume histogram analysis of the patients who developed pulmonary complications revealed  $V_{15}$  (volume of lung treated to 15 Gy) and  $V_{10}$  (volume of lung receiving 10 Gy) of 30% and 40%, respectively [28]. However, a later update of the study involving 110 patients reported the volume of lungs receiving 5 Gy ( $V_5$ ) of 47% as a significant risk factor for postoperative complications instead of  $V_{10}$  and  $V_{15}$  [29]. In another study using IMRT technique for preoperative esophageal cancer, 34% of the patients developed serious postoperative pulmonary complications. The authors of the study demonstrated that  $V_{15}$  of the right lung was predictive of pulmonary complications [26]. Thus, when combined with chemotherapy, the volume of normal lung receiving low radiation dose should be kept as low as possible. As an illustration, La et al. [30] reported no grade 3–4 pneumonitis in 30 patients with locally advanced esophageal cancer undergoing neoadjuvant chemoradiation with IMRT. The IMRT technique allowed sparing of a large volume of normal lung from radiation. The median  $V_5$  and the mean lung dose were respectively 53% and 10.9 Gy which may have accounted for the low morbidity. Thus, our tomotherapy plan lung  $V_5$  (41%),  $V_{10}$  (23%),  $V_{15}$  (16.4%) and mean lung dose (7.4 Gy) compared favorably with the results reported in the literature. The reduction of radiation dose to the lungs and cardiac ventricles was also associated with a significant reduction of maximum dose spinal cord dose with tomotherapy. Thus, a boost plan to achieve a higher dose to the GTV remained feasible without exceeding spinal cord dose tolerance to radiation. We repeat the CT scan of the chest and abdomen at 40 Gy to assess tumor shrinkage in patients undergoing

radiotherapy alone and definitive chemoradiation to assess the feasibility of a possible GTV boost. We will report in the future the clinical outcome of these patients. Alternatively, patients undergoing neoadjuvant preoperative chemoradiation may also benefit from tomotherapy to reduce postoperative complications. Our results may have important implications for future clinical trials. In a review of the literature on the management of esophageal cancer, dose escalation for locally advanced esophageal cancer in combination with chemotherapy was associated with significant toxicity when PTV dose exceeded 50 Gy [31]. All the studies reported in the review used 3DCRT with a 2-cm radial extension of the GTV accepted as standard PTV resulting in significant irradiation to the organs at risks for radiation damage because of the radiosensitization properties of chemotherapy [31]. Omitting chemotherapy to allow radiation dose escalation to 66 Gy was well tolerated but resulted in poor local control [32]. Thus, chemotherapy remains an essential component for the management of locally advanced esophageal cancer. An ideal treatment would combine concurrent chemotherapy and a radiotherapy technique that allows for radiation dose escalation while minimizing treatment toxicity. The integrated boost technique based on IMRT may allow for a more efficient dose escalation. Helical tomotherapy by virtue of its sharper dose gradient has been demonstrated to be more effective to spare the lungs and the heart from excessive radiation compared to IMRT and 3DCRT for esophageal cancer [33]. Daily MVCT and verification of radiation isodoses distribution allow accurate radiation dose delivery with a tighter PTV margin (3–5 mm) around the CTV and may decrease further the volume of myocardium radiated to 45 Gy when the GTV is located in close proximity to the heart. Thus, tomotherapy may become the ideal IMRT technique of the future because of its ability to reduce excessive cardiac and lungs irradiation. A higher GTV dose of 2.4 Gy/fraction for example instead of 2 Gy/fraction may allow for effective radiation dose escalation while minimizing irradiation to the normal tissues. The GTV would be treated to a total dose of 60 Gy instead of 50 Gy corresponding to a biologic equivalent dose of 73.4 Gy with an alpha and beta ratio of 10. We postulate that this fractionation may provide better local control for locally advanced esophageal cancer and may be feasible to decrease normal organs toxicity [34].

## Conclusion

Compared to three-dimensional conformal radiotherapy, image-guided radiotherapy based on helical tomotherapy may provide significant reduction of radiation dose to the lungs, cardiac ventricles, and spinal cord while delivering a higher dose to the gross tumor. This innovative technique should be investigated for radiation dose escalation in future prospective trials for esophageal cancer to increase local control and survival. Tomotherapy may also be beneficial in reducing postoperative complications following neoadjuvant chemoradiation for esophageal cancer.

## Conflict of interest

The authors have no conflict of interest and have no source of funding.

## References

- [1] Jemal A, Siegel R, Ward E, Hao Y, Xu J, Thun MJ. Cancer Statistics, 2009. *CA Cancer J Clin* 2009;59:225–49.
- [2] Cooper JS, Guo MD, Herskovic A, et al. Chemoradiotherapy of locally advanced esophageal cancer: long-term follow-up of a prospective randomized trial (RTOG 85–01). Radiation therapy oncology group. *JAMA* 1999;281:1623–7.
- [3] Al-Sarraf M, Martz K, Herskovic A, et al. Progress report of combined chemoradiotherapy versus radiotherapy alone in patients with esophageal cancer: an intergroup group study. *J Clin Oncol* 1997;15:277–84.

- [4] Bedenne L, Michel P, Bouche O, et al. Chemoradiation followed by surgery compared with chemoradiation alone in squamous cell carcinoma of the esophagus. *J Clin Oncol* 2007;25:1160-8.
- [5] Stahl M, Stuschke M, Lehmann N, et al. Chemoradiation with or without surgery in patients with locally advanced squamous cell carcinoma of the esophagus. *J Clin Oncol* 2005;23:2310-7.
- [6] Zhao KL, Shi XH, Jiang GL, et al. Late course accelerated hyperfractionated radiotherapy plus concurrent chemotherapy for squamous cell carcinoma of the esophagus: a phase III randomized study. *Int J Radiat Biol Phys* 2005;62:1014-20.
- [7] Nutting CM, Bedford JL, Cosgrove VP, Tait DM, Dearnaley DP, Webb S. A comparison of conformal and intensity-modulated techniques for esophageal radiotherapy. *Radiother Oncol* 2001;61:157-63.
- [8] Chandra A, Guerrero TM, Liu HH, et al. Feasibility of using intensity-modulated radiotherapy to improve lung sparing in treatment planning for distal esophageal cancer. *Radiother Oncol* 2005;77:247-53.
- [9] Zhang X, Zhao KL, Guerrero TM, et al. Four-dimensional computed tomography-based treatment planning for intensity-modulated radiation therapy and proton therapy for distal esophageal cancer. *Int J Radiat Oncol Biol Phys* 2008;72:278-87.
- [10] Mayo CS, Urie MM, Fitzgerald TJ, Ding L, Lo YC, Bogdanov M. Hybrid IMRT for treatment of cancers of the lung and esophagus. *Int J Radiat Biol Phys* 2008;71:1408-18.
- [11] Gayed IW, Liu HH, Yusuf SW, et al. The prevalence of myocardial ischemia after concurrent chemoradiation as detected by gated myocardial perfusion imaging in patients with esophageal cancer. *J Nucl Med* 2006;47:1756-62.
- [12] Gayed I, Gohar S, Liao Z, McAleer M, Bassett R, Yusuf SW. The clinical implications of myocardial perfusion abnormalities in patients with esophageal or lung cancer after chemoradiation therapy. *Int J Cardiovasc Imaging* 2009;25:487-95.
- [13] Lee TF, Fang FM, Chao PJ, Su TJ, Wang LK, Leung SW. Dosimetric comparisons of helical tomotherapy and step-and-shoot intensity-modulated radiotherapy in nasopharyngeal carcinoma. *Radiother Oncol* 2008;89:89-96.
- [14] Dawson LA, Jaffray DA. Advances in image-guided radiotherapy. *J Clin Oncol* 2007;25:938-46.
- [15] Beavis AW. Is tomotherapy the future of IMRT? *Br J Radiol* 2004;77:285-95.
- [16] Wu Q, Mohan R, Morris M, Lauve A, Schmidt-Ullrich R. Simultaneous integrated boost intensity-modulated radiotherapy for locally advanced head and neck squamous cell carcinomas. I: dosimetric results. *Int J Radiat Oncol Biol Phys* 2003;56:573-85.
- [17] Sasamoto R, Tsuchida E, Sagita T, Matsumoto Y, Abe E, Sasai K. Risks factors for enlargement of cardiac silhouette on chest radiography after radiotherapy for esophageal cancer. *Radiat Med* 2006;24:431-7.
- [18] Kumekawa Y, Kaneko K, Ito H, et al. Late toxicity in complete response cases after definitive chemoradiotherapy for esophageal squamous cell carcinoma. *J Gastroenterol* 2006;41:425-32.
- [19] Morota M, Gomi K, Kozuka T, et al. Late toxicity after definitive concurrent chemoradiotherapy for thoracic esophageal carcinoma. *Int J Radiat Oncol Biol Phys* 2009;75:122-8.
- [20] Ishikura S, Nihei K, Ohtsu A, et al. Long-term toxicity after definitive chemoradiotherapy for squamous cell carcinoma of the thoracic esophagus. *J Clin Oncol* 2003;21:2697-702.
- [21] Ruol A, Portale G, Castoro C, et al. Effects of neoadjuvant therapy on perioperative morbidity in elderly patients undergoing esophagectomy for esophageal cancer. *Ann Surg Oncol* 2006;14:3243-50.
- [22] Eskilsson J, Albertsson M, Mercke C. Adverse cardiac effects during induction chemotherapy treatment with cis-platin and 5-fluorouracil. *Radiother Oncol* 1988;13:41-6.
- [23] Pandeya N, Williams GM, Sadhegi S, Green AC, Webb PM, Whiteman DC. Associations of duration, intensity, and quantity of smoking with adenocarcinoma and squamous cell carcinoma of the esophagus. *Am J Epidemiol* 2008;168:105-14.
- [24] Freedman ND, Abnet CC, Leitzmann MF, et al. A prospective study of tobacco, alcohol, and the risk of esophageal gastric cancer subtypes. *Am J Epidemiol* 2007;165:1424-33.
- [25] Van Vulpen M, Field C, Raaijmakers CPJ, et al. Comparison step-and-shoot IMRT with dynamic helical tomotherapy IMRT plans for head and neck cancers. *Int J Radiat Biol Phys* 2005;62:1535-9.
- [26] Hsu FM, Lee YC, Lee JM, et al. Association of clinical and dosimetric factors with postoperative pulmonary complications in esophageal cancer patients receiving intensity-modulated radiation therapy and concurrent chemotherapy followed by thoracic esophagectomy. *Ann Surg Oncol* 2009;16:1669-71.
- [27] Hart JP, McCurdy MR, Ezhil M, et al. Radiation pneumonitis: correlation of toxicity with pulmonary metabolic radiation response. *Int J Radiat Oncol Biol Phys* 2008;71:967-71.
- [28] Lee HK, Vaporciyan AA, Cox JD, et al. Postoperative pulmonary complications after preoperative chemoradiation for esophageal carcinoma: correlation with pulmonary dose-volume histogram parameters. *Int J Radiat Oncol Biol Phys* 2003;57:1317-22.
- [29] Wang SL, Liao Z, Vaporciyan AA, et al. Investigation of clinical and dosimetric factors associated with postoperative pulmonary complications in esophageal cancer patients treated with concurrent chemoradiotherapy followed by surgery. *Int J Radiat Oncol Biol Phys* 2006;64:692-9.
- [30] La TH, Minn AY, Fisher GA, et al. Multimodality treatment with intensity modulated radiation therapy for esophageal cancer. *Dis Esophagus* 2010;23:300-8.
- [31] Berger B, Belka C. Evidence-based radiation oncology: esophagus. *Radiother Oncol* 2009;92:276-90.
- [32] Wu KL, Chen GY, Xu ZY, et al. Three-dimensional conformal radiation therapy for squamous cell carcinoma of the esophagus: a prospective phase I/II study. *Radiother Oncol* 2009;93:454-7.
- [33] Chen YJ, Liu A, Han C, et al. Helical tomotherapy for radiotherapy in esophageal cancer: a preferred plan with better conformal target coverage and more homogeneous dose distribution. *Med Dosim* 2007;32:166-71.
- [34] Vogelius IS, Westerly DC, Cannon GM, Bentzen SM. Hypofractionation does not increase radiation pneumonitis risk with modern conformal radiation delivery techniques. *Acta Oncol* 2010;49:1052-7.