



Contents lists available at ScienceDirect

## Oral Oncology

journal homepage: [www.elsevier.com/locate/oraloncology](http://www.elsevier.com/locate/oraloncology)

## Impact of image-guided radiotherapy to reduce laryngeal edema following treatment for non-laryngeal and non-hypopharyngeal head and neck cancers

Nam P. Nguyen<sup>a,\*</sup>, Dave Abraham<sup>a</sup>, Anand Desai<sup>a</sup>, Michael Betz<sup>b</sup>, Rick Davis<sup>a</sup>, Thomas Sroka<sup>a</sup>, Alexander Chi<sup>a</sup>, Steven Gelumauskas<sup>a</sup>, Misty Ceizyk<sup>a</sup>, Lexie Smith-Raymond<sup>a</sup>, Michelle Stevie<sup>a</sup>, Siyoung Jang<sup>a</sup>, Russ Hamilton<sup>a</sup>, Vincent Vinh-Hung<sup>b</sup>

<sup>a</sup> Department of Radiation Oncology, University of Arizona, Tucson, AZ, United States

<sup>b</sup> Department of Radiation Oncology, University Hospitals of Geneva, Geneva, Switzerland

## ARTICLE INFO

## Article history:

Received 24 March 2011

Received in revised form 3 June 2011

Accepted 3 June 2011

Available online xxxxx

## Keywords:

Head and neck cancer

IGRT

Laryngeal edema

Voice preservation

## SUMMARY

We would like to determine the effectiveness of image-guided radiotherapy (IGRT) to reduce laryngeal edema following treatment for head and neck cancer and to assess patient perception of voice and speech after treatment. We conducted a retrospective review of 44 patients undergoing radiation for non-laryngeal and non-hypopharyngeal head and neck cancers. Endoscopic and/or mirror examinations of the larynx were performed following radiotherapy at each follow-up visit. Laryngeal edema was assessed based on the Radiation Therapy Oncology Group grading scale. Patients were also asked to rate about the voice and speech quality relative to their pre-radiotherapy status. The mean laryngeal dose was 16.3 Gy (range: 11.7–45.5 Gy). At a median follow-up of 14 months (range: 2–31 months), three patients (7%) developed laryngeal edema (one grade 1, two grade 2). The mean laryngeal dose was respectively 20.3 Gy in two patients and 20.7 Gy in the third patient developing laryngeal edema. Except for one patient who continued to smoke and drink after radiotherapy, no patient reported any significant change in voice and speech quality after treatment. IGRT results in low rates and low severity of laryngeal edema following treatment for non-laryngeal and non-hypopharyngeal head and neck cancers and may preserve voice quality.

© 2011 Elsevier Ltd. All rights reserved.

## Introduction

Dysphonia and laryngeal edema are potential complications of radiotherapy for head and neck cancer affecting patient quality of life.<sup>1–3</sup> The impact of dysphonia on the ability to communicate effectively can result in severe distress and potential financial loss from sick leave.<sup>4</sup> Irradiation of the neck results in dryness of the submucosal laryngeal glands, abnormal vocal cord vibration, and in severe case laryngeal edema with resulting chronic dysphonia.<sup>5–7</sup> Laryngeal edema severity is correlated to the radiation dose delivered to the larynx.<sup>8</sup> For laryngeal and hypopharyngeal cancers, high doses to the larynx are unavoidable because of the tumor proximity, frequently resulting in long-term vocal cord edema.<sup>7</sup> However, for other head and neck cancer primary sites, conventional radiotherapy techniques still lead to excessive laryngeal irradiation and potential speech impairment.<sup>9,10</sup> Thus, reducing unnecessary laryngeal irradiation should be a goal for the treatment of all non-laryngeal and non-hypopharyngeal cancers.

Compared to conventional radiotherapy, intensity-modulated radiotherapy (IMRT) may reduce radiation doses including the larynx and pharynx.<sup>11</sup>

Image-guided radiotherapy (IGRT) is a more recent radiotherapy technique based on intensity-modulated radiotherapy (IMRT) providing superior sparing of normal tissues because of sharper dose gradient and greater accuracy of delivery.<sup>12,13</sup> We demonstrated in a previous study that IGRT may significantly reduce the radiation dose to the larynx compared to conventional IMRT.<sup>14</sup> In the current study, we would like to investigate whether IGRT can reduce the severity of laryngeal edema which may also potentially improve patient voice quality.

## Materials and methods

The medical records of 44 patients undergoing external beam radiotherapy for head and neck cancer with a Tomotherapy HiArt treatment system in non-laryngeal and non-hypopharyngeal sites at the University of Arizona Radiation Oncology department were retrospectively reviewed following institutional review board (IRB) approval. The Tomotherapy HiArt system was installed in December 2006 and the first patient was treated in January 2007. All patients were treated with the whole field (WF) IGRT

\* Corresponding author. Address: Department of Radiation Oncology, University of Arizona, 1501 N. Campbell Ave., Tucson, AZ 85724-5081, United States. Tel.: +1 520 694 7236; fax: +1 520 626 2032.

E-mail address: [NamPhong.Nguyen@yahoo.com](mailto:NamPhong.Nguyen@yahoo.com) (N.P. Nguyen).

**Table 1**  
Voice-related quality of life interview questions.

1. Interview questions related to voice quality
<b>Prior to radiotherapy:</b> Did you experience any difficulty with your speech or hoarseness of your voice? Were you a smoker? Were you a drinker? Did you work full time before radiotherapy? Did you experience any difficulty communicating verbally with your colleagues at work? Did you have any difficulty talking over the phone before the treatment started? Did your spouse or close family member notice any change of your voice before treatment?
<b>Following radiotherapy:</b> Do you have difficulty speaking with your colleagues? Did you need to retire after treatment? Do you have difficulty talking on the phone with family or friends? Do you notice any change in the quality of your voice? Has any member of your family noticed a change in your voice? Has anyone told you it is difficult to communicate with you because of your speech? Do you continue to smoke or drink after treatment? Do you think that radiotherapy had any effect on the quality of your voice or your ability to communicate with other people?
2. Subjective grading of voice quality
On a scale of 1–10, how do you rate the quality of your voice before and after treatment? (10 = ? 1 = ?)

technique. Prior to treatment, each patient was simulated in the supine position with a head and neck aquaplast mask for treatment immobilization. A computed tomography (CT) scan with and without intravenous (IV) contrast for treatment planning was performed in the treatment position. The head and neck areas from the vertex to the mid thorax were scanned with a slice thickness of 3 mm. CT scan with IV contrast was employed to outline the tumor and grossly enlarged cervical lymph node for target volume delineation. Radiotherapy planning was performed on the CT scan without contrast to avoid possible interference of contrast density on radiotherapy isodose distributions. Diagnostic positron emission tomography (PET)-CT scan planning for tumor imaging was also incorporated with CT planning when available for tumor imaging. A 0.5 cm bolus material was placed on any area of the skin involved by the tumor and on any palpable cervical lymph nodes.

Normal organs at risk for complication were outlined for treatment planning (spinal cord, brain stem, bilateral cochlea, mandible, parotid glands, larynx, pharyngeal muscles, bilateral eyes, and oral cavity). Radiation therapy dose was similar for patients in both groups using the integrated boost technique to decrease treatment toxicity.

The tumor and grossly enlarged lymph nodes (CTV1) on CT scan with a margin (PTV1) were treated to 70 Gy in 35 fractions (2 Gy/fraction). The margins were 5 mm–1 cm all around CTV1 depending on anatomic location. The areas at high risk-PTV2 (at least 1 cm around gross tumor and pathologic cervical lymph nodes) and low risk-PTV3 (subclinical regional lymph nodes with 5 mm margins) for tumor spread were treated respectively to 63 and 56 Gy in 35 fractions, respectively. Patients undergoing postoperative radiation were treated to 66, 59.4, and 54 Gy in 33 fractions to PTV1, PTV2, and PTV3, respectively. Minimal target coverage was 95% of the prescribed dose for all targets with at least 99% of the prescribed dose delivered to gross tumor and involved cervical lymph nodes. The lymph nodes in the ipsilateral neck including the retropharyngeal lymph nodes were treated to the base of skull if there was any cervical lymph node enlargement (or PET-positive lymph nodes). Contralateral uninvolved lymph nodes were treated prophylactically with the C1 vertebrae as the superior border. In case of bilateral cervical lymph node involvement, the bilateral neck was treated to the base of skull to avoid any marginal miss. Mean dose to the parotid was kept below 2600 cGy if there was no ipsilateral cervical lymph node enlargement. Dose constraints for other normal organs at risk (OAR) for complications were: spinal cord (45 Gy), brain stem (50 Gy), optic chiasm (45 Gy), mandible (70 Gy to less than 30% of the mandible). Doses to the larynx and pharyngeal muscles for non-laryngeal and non-hypopharyngeal cancers were kept between 20 and 40 Gy or below if feasible. The larynx and pharyngeal muscles (middle and inferior constrictors) were contoured from the hyoid bone cranially to the cricoid cartilage caudally following consultation with a radiologist. The larynx and pharyngeal muscles would have been effectively shielded from radiation with a laryngeal block in the conventional supraclavicular field of the split-field (SF) IMRT technique.<sup>15</sup>

Following treatment, regular follow-up visits were recommended at one month and every 3 months afterward. At each follow-up visit, a direct endoscopic or mirror exam of the larynx was performed as part of the routine clinical examination. The presence or absence of laryngeal edema was recorded. The severity of the laryngeal edema was graded according to the Radiation Therapy Oncology Group (RTOG) scale, in which: grade 0 = no edema, grade 1 = slight edema, grade 2 = moderate edema, grade 3 = severe edema, and grade 4 = necrosis.<sup>16</sup>

Patient voice quality was also assessed as compared to pretreatment speech. Patients having resumed a full time employment were asked if their speech interfered with their ability to interact at work. Patients having retired or become disabled after treatment were asked if they were able to converse normally by phone and whether there were any problems with speech intelligibility. A smoking and drinking history was also recorded, and referral to smoking cessation clinics and alcohol cessation support groups were recommended to patients who continued to smoke and drink. Table 1 illustrates the common interview questions and subjective grading scale to analyze voice-related quality of life before and after treatment.

## Results

We identified 44 patients with invasive squamous cell carcinoma located in non-laryngeal and non-hypopharyngeal sites treated at the University of Arizona Radiation Oncology department from 2007 to 2010. Median age at diagnosis was 57 year-old (range: 25–74-year-old). There were 41 males and three females. Disease sites were respectively: oropharynx (25), oral cavity (13), nasopharynx (1), parotid (4), and unknown (1). One patient had stage I disease, four patients had stage II disease while nine had stage III, 17 had stage IVA, nine had stage IVB, and three had stage IVC disease. One patient had neck recurrence following surgery for oral tongue cancer.

Six patients received radiotherapy alone, 32 received concurrent exclusive chemoradiation and 6 received postoperative chemoradiation.

Table 2 summarizes patient characteristics. Mean laryngeal dose was 16.3 Gy (range: 11.7–45.5 Gy). At a median follow-up of 14 months, laryngeal edema was recorded in three patients (7%). Severity was grade 1 in one patient and grade 2 in the other two. Mean laryngeal dose for these three patients was respectively 20.3 Gy for the first two patients, and 20.7 Gy for the third one. Of note all three patients developing edema after treatment continued to smoke after treatment despite repeated warnings. In addition, one of the patient with grade 2 laryngeal edema admitted to binge drinking during and following treatment.

One of the patient with grade 2 edema was the only patient in the study group reporting a permanent change in voice quality, probably in part due to his continued smoking and drinking. The other 41 patients reported no change in voice quality.

**Table 2**  
Patient characteristics.

Patient No.	44
Age	
Median	57
Range	25–74
Sex	
Male	41
Female	3
Squamous histology	44
Tumor sites	
Oropharynx	25
Oral cavity	13
Parotid	4
Nasopharynx	1
Unknown	1
Stages	
I	1
II	4
III	9
IVA	17
IVB	9
IVC	3
Recurrence	1
T stages	
Tx	1
T1	2
T2	19
T3	8
T4	13
Recurrence	1
Neck nodes	
N0	7
N1	13
N2	18
N3	5
Recurrence	1
Treatment	
Radiotherapy alone	6
Postoperative chemoradiation	6
Chemoradiation	32
Follow-up (months)	
Median	14
Range	2–31
Larynx examinations	
Direct	103
Indirect	33
Total	136
Smoking after treatment	12
Drinking after treatment	3

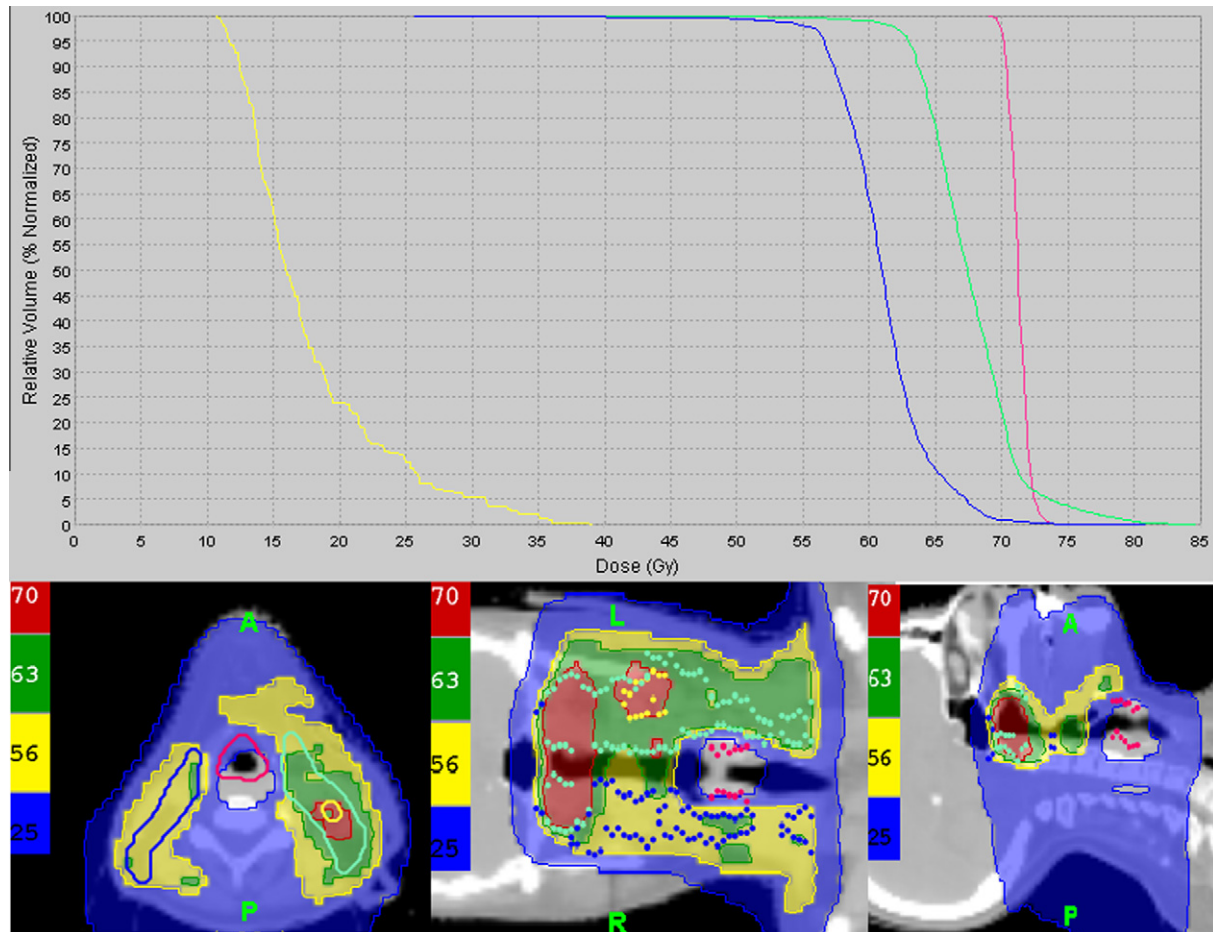
Overall, nine patients continued full-time employment, while 34 retired or filed for disability.

## Discussion

To our knowledge, this is the first study looking at the feasibility of using IGRT to decrease the risk of laryngeal edema and its benefit in preventing dysphonia after treatment. Radiation to the larynx has been reported to be associated with long-term laryngeal edema. Sanguinetti et al. reported a 52% rate of grade 2–3 laryngeal edema 15 months following radiation in 48 patients with non-laryngeal head and neck cancer.<sup>17</sup> Significant laryngeal edema was more likely to occur when the mean laryngeal dose exceeded 43.5 Gy.<sup>18</sup> A correlation between laryngeal edema and radiation dose was corroborated in other studies of head and neck cancer with early onset of laryngeal edema described as early as one week following treatment in a study of hyperfractionated radiotherapy which may become chronic afterward.<sup>19,20</sup> As a result of the radiation-induced edema, vocal cord dysfunction has been reported with resulting poor voice quality. Fung et al. observed significant abnormal vocal folds vibration on videostroboscopy in patients

irradiated for non-laryngeal head and neck cancer following mean laryngeal dose of 50 Gy or more.<sup>21</sup> Hamdam et al. reported poor voice quality 24–72 months after radiotherapy in 12 patients with non-laryngeal head and neck receiving mean laryngeal dose of 56 Gy.<sup>22</sup> In another study of 77 oropharyngeal cancer patients, 74% of the patients experienced mild to moderate dysphonia following radiation which impaired their quality of life.<sup>9</sup> In another study of 10 nasopharyngeal cancer patients, abnormal phonation was recorded on acoustic study.<sup>10</sup> In comparison to these studies, our very low rate of laryngeal edema and impaired voice quality suggests a clear benefit of reducing the laryngeal dose with IGRT. Additionally, all three of the patients developing laryngeal edema after treatment in our series reported persistent heavy smoking (2 packs/day) after radiotherapy, while admitted to binge drinking during and after treatment which resulted in alcohol-induced hepatitis. The laryngeal edema seen in these patients occurring after low mean laryngeal doses similar to those received by the other patients in our study group, may be at least in part attributable to their life style rather than due solely to radiotherapy. Even though we make an effort for smoking and drinking cessation, a large number of our patients are war veterans with severe post traumatic stress syndrome and continued to smoke after treatment. Of note, however, in the study group as a whole including these three patients as well as the larger number of patients continuing to smoke<sup>12</sup>, only one patient reported abnormal perception of voice and speech quality after treatment. Given the heterogeneity of tumor primary sites and treatment modalities, including six patients receiving postoperative radiation, we elected to evaluate voice quality by asking patients to self-assess voice and speech quality following radiotherapy, particularly in regard to professional and phone conversation performance. This simple method of judging voice quality provides us with a relatively accurate assessment of dysphonia severity as speaking over the phone remains a challenge for individuals with voice disorders given the limited frequency range transmitted over the phone (400–3400 Hz), which eliminates information from the high and low ends of the speech spectrum (normal: range 100–5000 Hz)<sup>23,24</sup>. A normal conversation over the phone thus requires a louder voice to improve intelligibility which is difficult to maintain over several minutes for individuals with dysphonia. Similarly, patients who maintaining full time employment after treatment would be expected to encounter difficulties at work in the presence of chronic dysphonia.<sup>25</sup> A speech-related quality of life questionnaire might have had provided more detailed information on patient voice quality, but was not feasible because of the retrospective nature of the study. We believe that IGRT, in our department Tomotherapy-based by virtue of its superior target coverage and sharper dose fall off compared to other static or dynamic IMRT delivery systems may provide better sparing of the larynx.<sup>12,13</sup> In a previous study, we demonstrated that IGRT can effectively spare the larynx and pharyngeal musculature in non-laryngeal and non-hypopharyngeal head and neck cancers without compromising target coverage even in the presence of cervical lymph nodes compared to IMRT.<sup>14</sup>

Fig. 1 illustrates low dose to the larynx and pharyngeal muscles in one patient with nasopharyngeal cancer. Despite the presence of an adjacent cervical lymph node treated to 70 Gy and the area of high risk for extra-capsular extension treated to 63 Gy, mean dose to the larynx was only 17.8 Gy. Shielding the larynx with a midline block would have under-dosed the neck node and the high risk PTV if one were to use the conventional split field IMRT technique because of the penumbra on the edge of the block. Thus, Tomotherapy provides excellent coverage of the PTV while decreasing dose to the larynx because of rapid dose fall off. The current study provides preliminary evidence that lowering the laryngeal dose with IGRT may effectively decrease the risk of laryngeal edema and improve patient voice quality.



**Figure 1** Illustration of the laryngeal sparing effect of Tomotherapy in a patient with locally advanced nasopharyngeal cancer: despite the presence of a left cervical node (yellow circle) adjacent to the larynx (red) treated to 70 Gy, and the area at risk for extracapsular extension (light green) treated to 63 Gy, mean laryngeal dose was only 17.8 Gy. A conventional supraclavicular field with a mid line block to shield the larynx would have under-dosed the node and high risk area and compromised cure rate.

We would like to emphasize that alteration in voice quality following radiotherapy for non-laryngeal and non-hypopharyngeal head and neck cancer is a complex process. Vocal fold lubrication is an important factor for normal phonation. Following laryngeal irradiation, the number of serous and mucinous cells within the larynx decrease and become atrophic producing dryness of the vocal folds and altering their vibration.<sup>5,26</sup> The vocal tract is defined as the airways above the vocal folds also plays an important role in vocal fold vibration and voice quality. Edema, fibrosis, and structural alteration of the vocal tract induced- by high radiation dose may affect speech intelligibility. Such vocal tract effects have been observed following irradiation of nasopharyngeal cancers where a longer closed phase of the glottic cycle was recorded by electroglottography (E.C.G.) compared to healthy individuals.<sup>10</sup> Acoustic analysis of voice quality also has demonstrated significant alteration of the voice pattern and poor quality of life in head and neck cancer patients undergoing chemoradiation for anatomic organ preservation.<sup>27</sup> A recent meta-analysis of head and neck cancer patients undergoing chemoradiation also corroborated the deterioration of voice and speech following treatment.<sup>28</sup> Thus, it is important for the clinician to be aware of patient dysphonia following head and neck irradiation which can be mitigated with voice therapy.<sup>29</sup> It is noteworthy that only 32% of the patients with complaints of dysphonia following chemoradiation were referred for speech therapy.<sup>27</sup> In a randomized study, patients with voice disorders following irradiation for glottic cancer were assigned

either to voice therapy or observation. Patients who underwent voice therapy had significant improvement in voice quality.<sup>29</sup>

Limitations of our study include its retrospective nature and the small number of patients enrolled. We did not have data from stroboscopic examination or speech-related quality of life questionnaires to provide a detailed analysis of vocal-folds vibration and speech quality following IGRT. In addition, we do not have a control group of non-laryngeal and non-hypopharyngeal cancer patients undergoing radiotherapy with the conventional technique of opposed laterals and a supraclavicular field to compare the severity of laryngeal edema and voice quality with our technique.

Nevertheless, we hope that our study will encourage other institutions to investigate the potential of IGRT to reduce the larynx dose during radiotherapy for non-laryngeal head and neck cancer, thus improving quality of life in survivors.

## Conclusion

Using image-guided radiotherapy based on helical Tomotherapy to reduce the mean laryngeal dose may result in a significant reduction of laryngeal edema for patients receiving radiotherapy for non-laryngeal and non-hypopharyngeal head and neck cancers.

Preservation of patient voice quality may thus be improved with this innovative radiotherapy technique. Further prospective studies should be performed to evaluate the potential of IGRT to improve patient quality of life following head and neck radiotherapy.



## Conflict of interest

The authors have no conflict of interest and have no source of funding.

## References

- Franchin G, Minatel E, Gobitti C, et al. Radiotherapy for patients with early stage glottic carcinoma. *Cancer* 2003;**98**(4):765–72.
- Chatani M, Matayoshi Y, Masaki N, Teshima T, Inoue T. Radiation therapy for early glottic carcinoma. The final results of prospective randomized study concerning radiation field. *Strahlenther Onkol* 1996;**172**(3):169–72.
- Dietz A, Rudat V, Nollert J, Helbig M, Vanselow B, Weidauer H. Chronic laryngeal edema as a late reaction to chemoradiotherapy. *HNO* 1998;**46**(8):731–8.
- Jones SM, Carding PN, Drinnan MJ. Exploring the relationship between severity of dysphonia and voice-related quality of life. *Clin Otolaryngol* 2006;**31**(5):411–7.
- Nakashima T, Tomita H, Tsuda S, Chitose S. Radiotherapy of the neck influences the distribution of laryngeal secretory glands. *J Laryngol Otol* 2005;**119**(12):976–80.
- Deore SM, Supe SJ, Sharma V, Dinshaw KA. Importance of dose per fraction and estimation of an alpha/beta value for the late complications of the vocal cords. *Strahlenther Onkol* 1991;**167**(10):608–11.
- Verdonck-de Leeuw IM, Hilgers FJ, et al. Multidimensional assessment of voice characteristics after radiotherapy for early glottic cancer. *Laryngoscope* 1999;**109**(2Pt1):241–8.
- Fu KK, Woodhouse RJ, Quivey JM, Phillips TM, Dedo HH. The significance of laryngeal edema following radiotherapy of carcinoma of the vocal cords. *Cancer* 1982;**49**(4):655–8.
- Thomas L, Jones TM, Tandon S, Carding P, Lowe D, Rogers S. Speech and voice outcomes in oropharyngeal cancer and evaluation of the University of Washington quality of life speech domain. *Clin Otolaryngol* 2009;**34**(1):34–42.
- Lin E, Hwang TZ, Hornibrook J, Ormond T. Voice of postradiotherapy nasopharyngeal carcinoma patients: Evidence of vocal cord tract effect. *J Voice* 2008;**22**(3):351–64.
- Roe JW, Carding PN, Dwivedi RC, et al. Swallowing outcomes following intensity modulated radiation therapy (IMRT) for head and neck cancer – A systemic review. *Oral Oncol* 2010;**46**(10):727–33.
- Jacob V, Bayer W, Astner ST, Busch R, Kneschaurek P. A planning comparison of dynamic IMRT for different collimator leaf thicknesses with helical tomotherapy and RapidArc for prostate and head and neck tumors. *Strahlenther Onkol* 2010;**186**(9):502–10.
- Murthy V, Master Z, Gupta T, et al. Helical tomotherapy for head and neck squamous cell carcinoma: dosimetric comparison with linear accelerator-based step and shoot IMRT. *J Cancer Res Treat* 2010;**6**(2):194–8.
- Nguyen NP, Ceizyk M, Vos P, et al. Effectiveness of image-guided radiotherapy for laryngeal sparing in head and neck cancer. *Oral Oncol* 2010;**46**(4):283–6.
- Amdur RJ, Li JG, Liu C, Hinerman RW, Mendenhall WM. Unnecessary laryngeal irradiation in the IMRT era. *Head Neck* 2004;**26**(3):257–63.
- Cox JD, Stetz JA, Pajak TF. Toxicity criteria of the Radiation Therapy Oncology Group (RTOG) and the European organization for research and treatment of cancer (EORTC). *Int J Radiat Oncol Biol Phys* 1995;**31**(5):1341–6.
- Rancati T, Fiorino C, Sanguinetti G. NTCP modeling of subacute/late laryngeal edema scored by fiberoptic examination. *Int J Radiat Oncol Biol Phys* 2009;**75**(3):915–23.
- Sanguinetti G, Adapala P, Endres EJ, Brack C, Fiorino C, Sormani MP, et al. Dosimetric predictor of laryngeal edema. *Int J Radiat Oncol Biol Phys* 2007;**68**(3):741–9.
- Nguyen TD, Panix X, Legros M, Froissard D. Hyperfractionated radiotherapy in advanced squamous cell carcinoma of the head and neck. *Int J Radiat Oncol Biol Phys* 1983;**9**:393–5.
- Nguyen TD, Demange L, Froissard D, Panix X, Loirette M. Rapid hyperfractionated radiotherapy. Clinical results in 178 advanced squamous cell carcinoma of the head and neck. *Cancer* 1985;**56**(1):16–9.
- Fung K, Yoo J, Leeper HA, Hawkins S, Heeneman H, Doyle PC, et al. Vocal function following radiation for non-laryngeal versus laryngeal tumors of the head and neck. *Laryngoscope* 2001;**111**(11 Pt1):1920–4.
- Hamdam A, Geara F, Rameh C, Hussein HT, Eid T, Fuleihan N. Vocal changes following radiotherapy to the head and neck for non laryngeal tumors. *Eur Arch Otolaryngol Head Neck Surg* 2009;**266**(9):1435–9.
- Nilsson M, Kleijn WB. Avoiding over-estimation in bandwidth extension of telephony speech. *Proceedings of the IEEE International conference on Acoustics, Speech, and Signal processings* 2001;**2**. p. 869–972.
- Drager KDR, Hustad KC, Gable KL. Telephone communication: synthetic and dysarthric speech intelligibility and listeners preferences. *Augmentive Alternative Communication* 2004;**20**. p. 103–112.
- Scott S, Robinson K, Wilson JA, Mackenzie K. Patient-reported problems associated with dysphonia. *Clin Oncol* 1997;**22**(1):37–40.
- Sato K, Nakashima T. Effect of irradiation on the human laryngeal glands. *Ann Otol Rhinol Laryngol* 2008;**117**:734–9.
- Campos RJDS, Maciel CTV, Cesca MG, Leite ICG. Voice analysis after cancer treatment with organ preservation. *Head Neck Oncol* 2011;**3**:19.
- Jacobi I, van der Molen L, Huiskens H, van Rossum MA, Hilgers FJM. Voice and speech outcomes of chemoradiation for advanced head and neck cancer: a systemic review. *Eur Arch Otorhinolaryngol* 2010;**267**:1495–505.
- van Gogh CDL, Verdonck-de Leeuw IM, Boon-kamma BA, Rinkel RNPM, de Bruin JA, Langendijk JA, et al. The efficacy of voice therapy in patients after treatment for early glottic carcinoma. *Cancer* 2006;**106**:95–105.